Paratubal Atypical Proliferative Serous Tumour in a Young Adolescent Female - A Diagnostic Dilemma

Monika Garg[1], Navneet Kaur[2], Kanwardeep Kaur[3], Amrinder Kaur[4], Chandrika[5]

ABSTRACT

Introdcution: Paratubal atypical proliferative serous tumours are rare usually arising from the mesothelium or from the remnants of mesonephric and paramesonephric ducts. We present a rare case of paratubal borderline serous tumour in a young adolescent female presenting clinically as an omental cyst.

Case Report: A 14-year old unmarried female presented with abdominal pain in right iliac fossa. MRI revealed a well demarcated space occupying lesion in the pelvis almost in midline measuring 12x11x8cm. Lesion was abutting and displacing overlying bowel loops with likely adhesions suggestive of complex omental cyst. The patient underwent cystectomy. The final histopathologic report confirmed the cyst as Paratubal atypical proliferative serous tumour.

Conclusion: We experience a rare case of atypical proliferative serous tumour of paratubal origin. The patient was youngest than any of the other cases reported in the literature. Fertility sparing surgery should be considered as a standard treatment of borderline paratubal tumour, if patient desires future fertility.

Keywords: Cystadenoma, Fallopian Tube, Neoplasms, Ovary, Paraovarian Cyst, Peritoneum

INTRODUCTION

Paratubal borderline tumours are very rare neoplasms and represent 10-20% of all adnexal tumours.[1] They usually arise from mesothelium that covers the peritoneum or from remnants of mesonephric and paramesonephric duct. Paratubal serous tumours show epithelial proliferations without stromal invasion.[2] Microscopically they are covered by unstratified flat to cuboidal to ciliated columnar epithelial cells. They usually have an underlying thin layer of smooth muscle. Although paratubal cyst is common incidental findings during gynaecologic surgery, borderline serous tumours are rare.[3]

Here, we are presenting a unique case of paratubal borderline serous tumour in a young adolescent female presented clinically as omental cyst and reported histologically as atypical proliferative serous borderline tumour which is a diagnostic dilemma and should be differentiated from an ovarian and fallopian tubal serous borderline tumour.

CASE REPORT

A 14-year-old unmarried female, referred to our hospital with abdominal pain in right iliac fossa for 4 days. She had similar complaints 6 months back for which she had taken analgesics. On examination, pain was dull aching, diffuse, non- radiating. There was no postural or diurnal variation in pain. No history of hypothyroidism, diabetes mellitus, weight loss or loss of appetite. No family history of any malignancy. Patient had menarche one year back.

Ultrasonography revealed a cystic mass in the pelvis. MRI revealed a well demarcated space occupying lesion in the pelvis almost in midline measuring 12x11x8cm showing haemorrhagic and mucinous component. Lesion was abutting and displacing overlying bowel loops with likely adhesions suggestive of complex omental cyst. The left ovary and the fallopian tube were completely separated from the cyst. (Figure 1,2) Serum CA 125, CA 19-9, CEA and AFP levels were 41.8 IU/mL, 10.08 IU/mL, 2.39 ng/mL and 4.23 ng/mL respectively (within normal range). There was no evidence of ascites, peritoneal seedling, pelvic and para- aortic lymphadenopathy. Exploratory laparotomy with removal of cyst was done. Grossly, the cyst measured 9 x 6.5 x 3 cm, containing sero-mucinous fluid with papillary projections noted in the luminal surface of the cyst. (Figure 2)

Histologically, cystic tumour was seen lined by complex papillae with nuclear stratification projecting into the lumen. Hierarchical pattern of branching with occasional hob-nailing and clearing was noted. The nuclear atypia, hyperchromasia, stratification and tufting constituted >10% of the tumour. No invasive features seen. The tumour was surrounded by fibromuscular layer. The sections from attached fallopian tube showed hyperplastic epithelium. The final histopathological diagnosis of atypical proliferative serous tumour of paratubal origin was given. (Figure 3,4,5)

[1]Associate Professor, Department of Pathology, Government Medical College, Patiala. Punjab.147001, [2]Associate Professor Department of Pathology, Government Medical College, Patiala. Punjab.147001, [3]Assistant Professor Department of Pathology, Government Medical College, Patiala. Punjab.147001, [4]Assistant Professor Department of Pathology, Government Medical College, Patiala. Punjab.147001, [5]Resident Department of Pathology, Government Medical College, Patiala. Punjab.147001, India

Corresponding author: Dr. Amrinder Kaur, Assistant Professor Department of Pathology, Government Medical College, Patiala. Punjab.147001, India

How to cite this article: Monika Garg, Navneet Kaur, Kanwardeep Kaur, Amrinder Kaur, Chandrika. Paratubal atypical proliferative serous tumour in a young adolescent female - a diagnostic dilemma. International Journal of Contemporary Medical Research 2020;7(3):C7-C9.

DOI: http://dx.doi.org/10.21276/ijcmr.2020.7.3.34

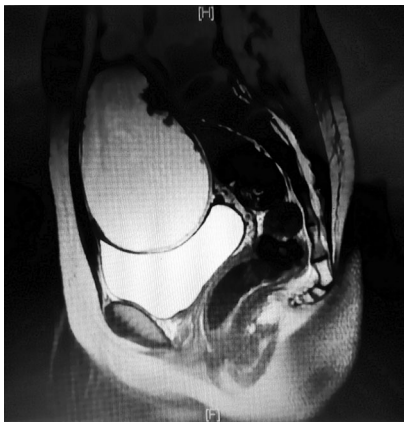

Figure-1: Well demarcated SOL in the pelvis superior to urinary bladder measuring 12x11x8 cm. The lesion show hyperintense signal on T1 with intermediate signal intensity solid component at the periphery.

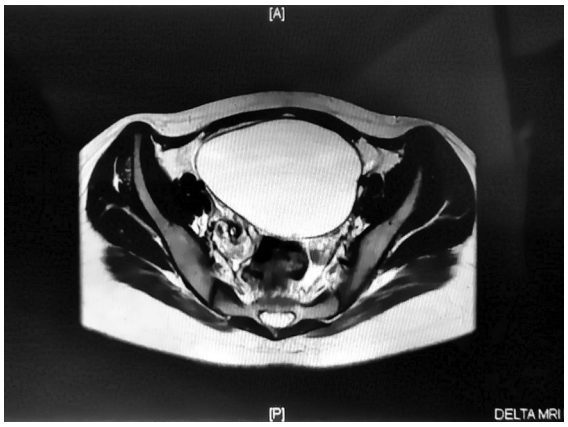

Figure-2: Hyperintense lesion seen on T2 and T2FS. Both ovaries and uterus are separately defined from the lesion.

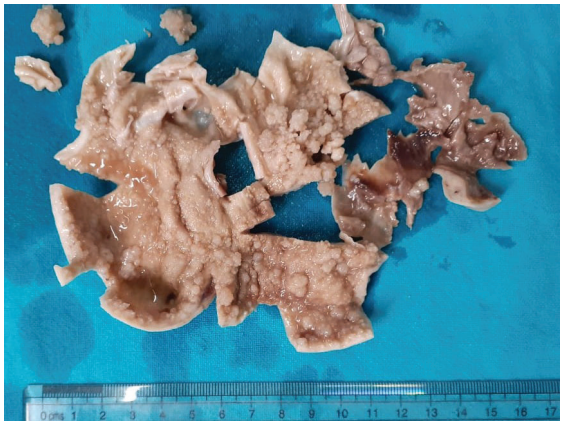

Figure-3: Grossly, the tumour had bosselated external surface with inner surface thrown into multiple papillary projections.

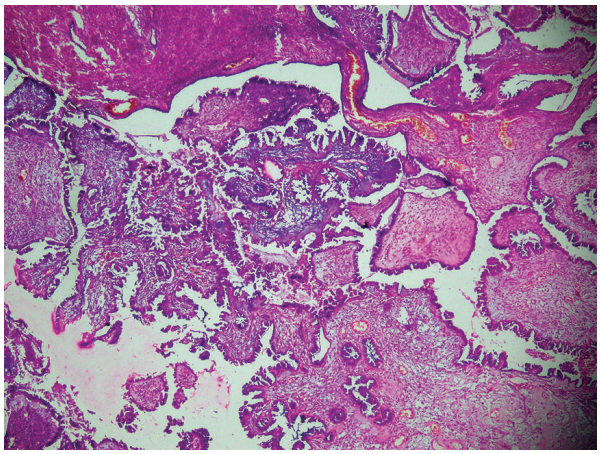

Figure-4: Photomicrograph showing multiple papillary projections with nuclear stratification, moderate pleomorphism, mucinous and hierarchical pattern of branching. (10X magnification)

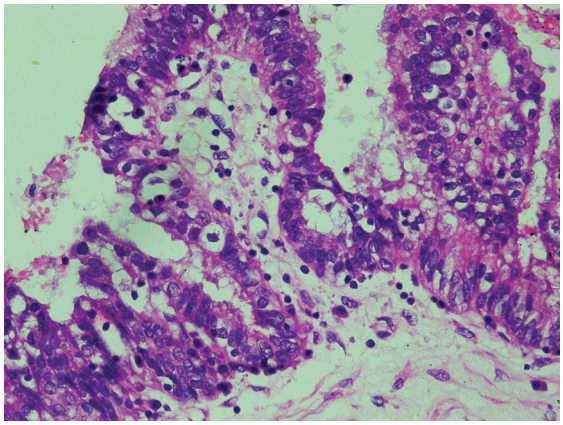

Figure-5: Papillary tumour revealing stratification, occasional clearing and hob-nailing. (40X magnification)

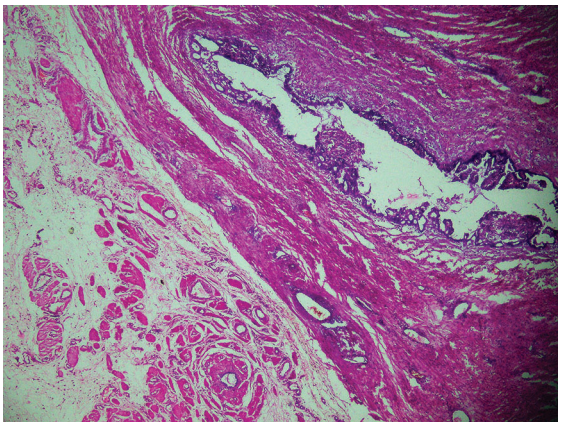

Figure-6: Prominent layer of fibromuscular tissue surrounding the tumour (10X magnification)

DISCUSSION

Paratubal cyst is cystic lesions attached to the fimbria within the mesosalpinx and broad ligament and originates from the mesonephric (Wolffian duct), paramesonephric (Mullerian duct) or mesothelium. Paratubal cyst is common. Hydatid cyst of Morgagni is by far the most common paramesonephric cyst accounting for 5% of all adnexal cysts.[4] On the other hand paratubal borderline tumours are very rare, they have been reported only as case reports in the literature.[3]

The average age noted by most authors is 31 years.[3,5] Our case is youngest of any case reported till date as per literature.[6] Atypical proliferative serous borderline tumour of paratubal origin is histologically indistinguishable from primary ovarian tumour. Preoperative diagnosis of these tumours is usually difficult and they are commonly mis-diagnosed as other pelvic cystic masses as in our case. In one previous report, preoperative diagnosis of these tumours by imaging findings was possible only in 6.7% of cases and 73.3% were

misdiagnosed as tumour of ovarian origin.[4,6,7]

Generally the presence of solid component and mural nodules in the lumen and the wall of cystic tumours indicated their malignant potential.[8] In our case, the tumour was diagnosed as complex omental cyst and showed hyperintense signal on T2N1 and some intermediate signal intensity solid component at the periphery. The tumour was abutting and displacing the overlying bowel loops. So, it is recommended that presence of nodules or solid component within the cyst and papillary projection within the cyst wall should be searched carefully by pathologist to know the extent of invasion and exact origin of the tumour.

Grossly the tumour was thin walled, unilocular and had bosselated external surface. Microscopically, it was characterized by features of borderline tumour including cellular proliferation, stratification of epithelial lining of papillae, nuclear atypia and increased mitotic activity, but without destructive stromal invasion. Epithelial tumours of Mullerian type have a thin layer of smooth muscle surrounding the tumour as seen in our case.

Differential diagnosis included serous borderline tumours of ovarian and fallopian tube, borderline mucinous tumour, borderline tumour of mesothelial origin. Points in favour of borderline serous tumour in our case were hierarchical pattern of branching, variable degree of nuclear atypia, columnar epithelial cells resembling secretory cells of fallopian tube admixed with variable number of ciliated cells (>10%). Serous Borderline Tumour can secrete thick mucin. Mucin is largely confined to lumen and the superficial cytoplasm of the cells unlike mucinous tumours where cyst is lined by columnar mucinous epithelium of gastric and intestinal differentiation, with papillary infoldings. Nuclei of mucinous tumours are basally located with evenly distributed chromatin. Mullerian and mesonephric remnants lie in the broad ligament and are lined by low columnar to cuboidal, non- ciliated cells and surrounded by prominent layer of smooth muscle.[9]

Paratubal borderline serous tumour is similar to ovarian tumour in histological appearance, but its clinical course and prognosis are not well understood.[2,10]

Tumour markers are used to monitor recurrence of disease rather than diagnose it.[6] CA 125, CA19-9, CEA is most consistently elevated in epithelial tumours, but can be expressed in number of gynaecological (endometrial, fallopian tube) and non-gynaecological (pancreatic, breast, colon, lung) cancer, as well as in number of benign conditions including endometriosis. Our case reviewed mild elevated CA125 level similar to our study done by Itani et al.[11]

There is currently no standard treatment for paratubal borderline tumours owing to its rarity.[12] Since our case was young, fertility sparing surgery performed, however close follow-up is mandatory to detect recurrent disease after conservative surgery. Combining routine ultrasonography and tumour markers during follow-up examinations were suggested.

CONCLUSION

We experience a rare case of atypical proliferative serous tumour of paratubal origin. The patient was youngest than any of the other case reported to date. Additional reports on these tumours' types are required to establish standard treatment and pathogenesis of these tumours.

REFERENCES

1. Lashin ME-B, Abdelwahab MM, Elnagar WM. Para Ovarian Cyst in 16 Years Old Female; Borderline Ovarian Tumor: A Case Report. Am J Med Case Rep. 2018 ;6:233–6.
2. Seamon LG, Holt CN, Suarez A, Richardson DL, Carlson MJ, O'Malley DM. Paratubal borderline serous tumors. Gynecol Oncol. 2009;113:83–5.
3. Shin Y-J, Kim J-Y, Lee HJ, Park J-Y, Nam J-H. Paratubal serous borderline tumor. J Gynecol Oncol. 2011;22:295.
4. Savelli L, Ghi T, De Iaco P, Ceccaroni M, Venturoli S, Cacciatore B. Paraovarian/paratubal cysts: comparison of transvaginal sonographic and pathological findings to establish diagnostic criteria. Ultrasound Obstet Gynecol. 2006;28:330–4.
5. Alaoui FZF, Fatemi HE, Chaara H, Melhouf MA, Amarti A. Borderline paratubal cyst: a case report. Pan Afr Med J. 2012;13:53.
6. Baek JC. Paratubal borderline serous tumor in a postmenopausal woman: a case report. Pan Afr Med J. 2019;32:129.
7. Barloon TJ, Brown BP, Abu-Yousef MM, Warnock NG. Paraovarian and paratubal cysts: preoperative diagnosis using transabdominal and transvaginal sonography. J Clin Ultrasound JCU. 1996;24:117–22.
8. Zhao SH, Qiang JW, Zhang GF, Boyko OB, Wang SJ, Cai SQ, et al. MRI appearances of ovarian serous borderline tumor: Pathological correlation: MRI in Ovarian Serous Borderline Tumor. J Magn Reson Imaging. 2014;40:151–6.
9. Hauptmann S, Friedrich K, Redline R, Avril S. Ovarian borderline tumors in the 2014 WHO classification: evolving concepts and diagnostic criteria. Virchows Arch. 2017;470:125–42.
10. Terek MC, Sahin C, Yeniel AO, Ergenoglu M, Zekioglu O. Paratubal Borderline Tumor Diagnosed In The Adolescent Period: A Case Report And Review of The Literature. J Pediatr Adolesc Gynecol. 2011;24:e115–6.
11. Itani Y, Itoh K, Adachi S, Koyama M, Kimura T, Chin R, et al. Malignant epithelial tumor of unknown origin of the broad ligament. Arch Gynecol Obstet. 2002;267:113–6.
12. Lee S, Ahn KH, Park HT, Hong SC, Lee YJ, Kim IS, et al. Paratubal Borderline Malignancy: A Case of a 17-Year-Old Adolescent Female Treated with Laparo-Endoscopic Single-Site Surgery and a Review of the Literature. J Pediatr Adolesc Gynecol. 2016;29:74–6.

Source of Support: Nil; **Conflict of Interest:** None

Submitted: 17-02-2020; **Accepted:** 15-02-2020; **Published:** 20-03-2020