ORIGINAL RESEARCH

Diagnostic Utility Of Fine Needle Aspiration Cytology In Superficially Palpable Supraclavicular Lymph Nodes

Garima Gupta,[1] Ranjan Agrawal,[2] Parbodh Kumar[3]

ABSTRACT

Introduction: Fine needle aspiration cytology as a first line of investigation has assumed importance in diagnosing a variety of disease process.
Aim: The aim of this study was to assess the diagnostic value of fine needle aspiration cytology in the evaluation of palpable supraclavicular lymph nodes.
Materials and methods: A prospective study was done over a 1 year period from January 2013 to December 2013. All patients presenting with palpable supraclavicular lymph nodes to the Department of Pathology, Rohilkhand Medical College and Hospital were subjected to an FNAC procedure. Fine needle aspiration cytology was performed on 159 patients.
Results: The right supraclavicular lymph node was enlarged in 57.9% cases, while the left supraclavicular lymph node alone was palpable in 40.9% cases and in 1.2% cases bilateral supraclavicular lymph nodes were palpable. Cytological diagnoses were categorized as reactive (20.1%), tubercular (37.7%),granulomatous (12.6%). Hodgkin lymphoma (3.1%), Non Hodgkin lymphoma(1.3%) and metastasis (25.2%). Of a total of 47cases of malignancy, 85.1% were non-lymphoid and 14.9% were lymphoid. Of the 40 cases of metastatic disease, three major types of malignancy found in supraclavicular lymph nodes were Squamous cell carcinoma (25 cases), adenocarcinoma (12cases) and others (5 cases). Adenocarcinoma tended to metastasize to the left supraclavicular lymph node.
Conclusion: The fine needle aspiration cytology can be used as a first line investigation in the evaluation of supraclavicular lymphadenopathy due to its low cost, simplicity and minimal invasiveness.

Keywords: Supraclavicular lymph node, metastasis, fine needle aspiration cytology.

How to cite this article: Garima Gupta, Ranjan Agrawal, Parbodh Kumar. Diagnostic utility of fine needle aspiration cytology in superficially palpable supraclavicular lymph nodes Int J Cont Med Res. 2015;2(1):1-6

[1]Post Graduate student, [2]Professor, [3]Professor and Head of Department , Department of Pathology, Rohilkhand Medical College & Hospital, Bareilly, India

Corresponding author: Garima Gupta, Post Graduate student, Department of Pathology, Rohilkhand Medical College & Hospital, Bareilly, India

Source of Support: Nil

Conflict of Interest: None

INTRODUCTION

Swelling in the neck could be due to disease involving salivary glands, lymph nodes, thyroid or skin. Lymphadenopathy is one of the most common problems encountered in neck. The cause may range from an infectious process to a malignant disease. Diagnosing the cause of these enlarged lymph nodes has always been a challenge for the physicians. Fine needle aspiration cytology (FNAC) helps solving the cause of enlarged lymph nodes. It is a tool to obtain material from a swelling for cytological examination, performed as an outpatient procedure. Superficial swellings are approached directly however deep swellings require ultrasound guidance. It has potential benefits over the other diagnostic modalities that have increased the utility of FNAC in recent past. It is simple, cost effective procedure that is minimally invasive with almost no complications. Results obtained by FNA are quick as compared to histopathological diagnosis. FNA of superficial lesions need no anesthesia eliminating the risk of

complications associated with anesthesia. No scar is formed at the site of FNA; other diagnostic modalities like incision biopsy or excision biopsy leave a scar.1 In case of suspected malignancy, FNAC is the best choice as it does not cause spread of tumor through the skin tract .2 FNAC can also be of therapeutic use in a cystic swelling. Common causes of neck lymphadenopathy are inflammation, reactive hyperplasia, lymphoproliferative disorder and metastatic disease. The sensitivity of FNAC for the diagnosis of lymphadenopathy averages 90% with a specificity of 95% .3 The high degree of accuracy, low costs and minimally disruptive nature of the procedure makes FNAC a highly desirable alternative to open biopsy for investigation of lymphadenopathy.1

The present study aimed at analyzing the FNAC of supraclavicular lymph nodes and studied the cytomorphological patterns of these lymph nodes along with diagnostic utility of FNAC as the first line investigation for the evaluation of palpable supraclavicular lymph nodes.

MATERIALS AND METHODS

A prospective study was done over a 1 year period from January 2013 to December 2013. All patients presenting with palpable supraclavicular lymph nodes to the Department of Pathology during one year period (January2013-december 2013) were subjected to an FNAC procedure. 159 patients presented with palpable supraclavicular lymph nodes during this period and FNAC was performed on these cases. Aspirates were procured by using a 21 gauge needle attached to a 5 ml syringe. One to two passes were performed. The content of the needle was carefully expressed on the glass slides and then by gently laying one slide over the slide holding the material, permitting the weight of the spreader to spread the material, the slides were pulled apart horizontally. Some of the slides were immediately fixed by immersing them in equal concentration of alcohol and ether for 30minutes without allowing them to dry. These were stained by Papanicolau's technique. The rest of the slides were air dried and fixed by immersing in methanol for 1-2 minutes and stained by May-Grunwald-Giemsa and Leishman-Giemsa techniques. Cytological evaluation was performed by examining these slides under microscope. The cytological diagnosis from each case was based on cytomorphology and available clinical information. The results were categorized as reactive, tubercular, granulomatous, lymphoma or metastasis.

RESULTS

A total of 159 FNACs were studied and the ages of the patients ranged from 7 to 80 years with a male to female ratio of 1:1.6. The right supraclavicular lymph node was enlarged in 92 of 159 (57.9%) of the cases, while the left supraclavicular lymph node was only palpable in 65 of 159 (40.9%) cases. In 2 of 159 (1.2%) cases, bilateral supraclavicular lymph nodes were palpable. The size of the lymph nodes varied from 0.5 to 5 cm. The lymph nodes in tuberculosis were multiple, firm and matted; while the majority of lymph nodes having metastatic disease were firm and fixed. Table 1 summarizes the FNAC diagnoses of supraclavicular lymph nodes.

Of the 159 cases, 20(12.6%) were granulomatous lymphadenitis, 60(37.7%) were tubercular lymphadenitis (Fig. 1), 32 (20.1%) were reactive lymphadenitis, 5 (3.1%) were hodgkins lymphoma, 2 (1.3%) were non hodgkins lymphoma (Fig.2) and 40 (25.2%) showed metastatic disease. Cases of tubercular lymphadenitis showed acid fast bacilli using the Ziehl-Neelsen stain. Right supraclavicular lymph nodes were more frequently involved by tuberculosis than left supraclavicular lymph nodes. Of the 47 cases of malignancy, 40 (85.1%) were non lymphoid and 7 (14.9%) were lymphoid. Three major types of malignancy were found in the supraclavicular lymph nodes in the metastatic disease. They were 23 cases of squamous cell carcinoma (Fig. 3), 12 cases of adenocarcinoma (Fig. 4) and 5 cases were included in others (small cell carcinoma, papillary thyroid carcinoma). Lymphoid neoplasm included 2 cases of Non-Hodgkin lymphoma in males and 5 cases of Hodgkin

FNAC Diagnosis	No of cases	Male	Female
Granulomatous lymphadenitis	20	10	10
Tubercular lymphadenitis	60	20	40
Reactive lymphadenitis	32	13	19
Hodgkin lymphoma	5	-	5
Non Hodgkin lymphoma	2	2	-
Metastasis	40	15	25
Total	**159**	**60**	**99**

Table-1: FNAC diagnosis of Supraclavicular Lymph Nodes

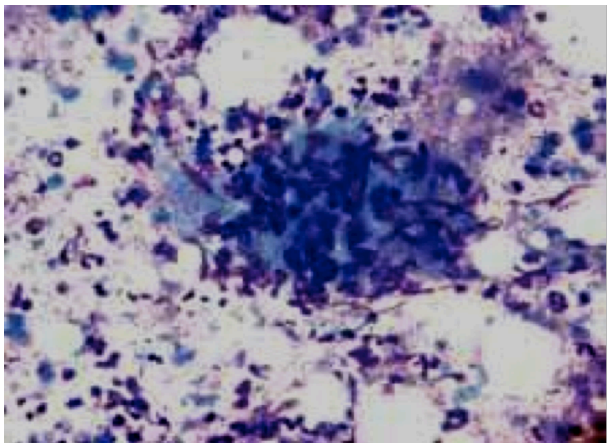

Figure - 1: Tubercular lymphadenitis(LGx400)

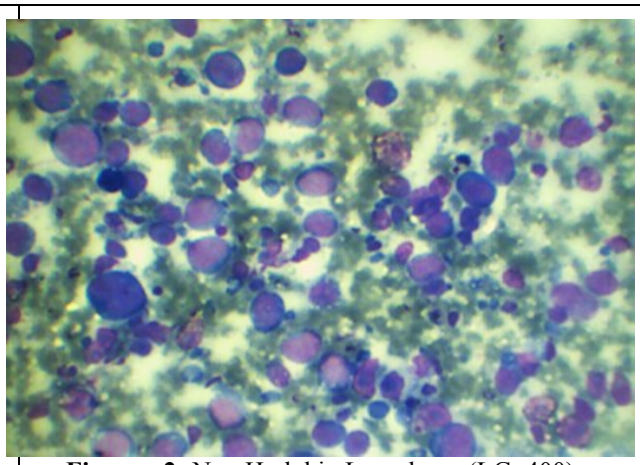

Figure - 2: Non Hodgkin Lymphoma(LGx400)

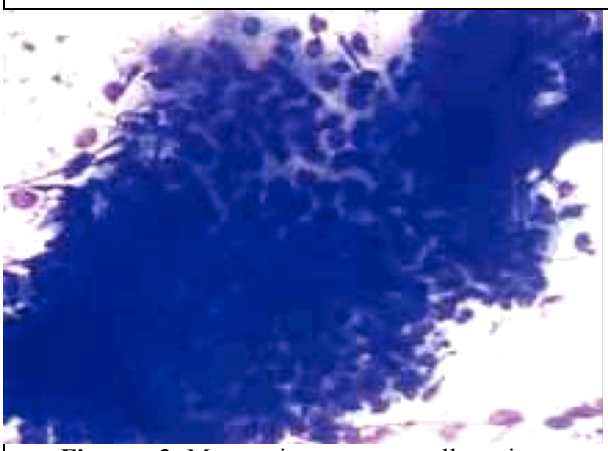

Figure - 3: Metastatic squamous cell carcinoma (LGx400)

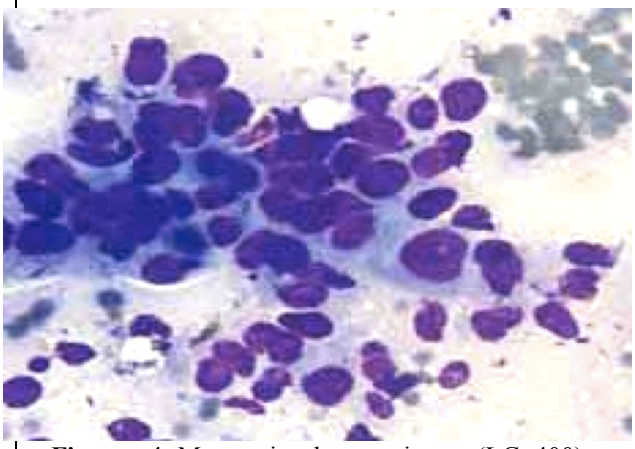

Figure - 4: Metastatic adenocarcinoma (LGx400)

lymphoma in females. Both Non-Hodgkin and Hodgkin lymphoma showed no site predilection between right and left supraclavicular lymph nodes. Adenocarcinoma from all sites tended to metastasize to the left supraclavicular lymph node. Squamous cell carcinoma metastasized equally in right and left supraclavicular lymph nodes. Small cell carcinoma did not show any predilection and all metastasized from lungs.

DISCUSSION:

Supraclavicular lymph nodes are easily accessible to palpation and they are a common repository of metastatic malignancies.[4] FNAC of supraclavicular lymph nodes is useful as a first line of investigation due to its simplicity and cost effectiveness as well as easy sample accessibility.[5] Studies have indicated the value of

FNAC in evaluating the palpable supraclavicular lymph nodes.[6-10] This study shows that FNAC is useful in diagnosing infectious, reactive and neoplastic processes which was also found in above studies. A prompt diagnosis was available to us where biopsies are not commonly done. In the present study tubercular lymphadenitis was a cause of 37.7% of the supraclavicular lymphadenopathi- es. Similar finding (36%) was also noted by Ahmed et al in his study.[3] But this result was high compared to the studies of Gupta N et al[11] (13.5%) and Nasuti JF et al[8] (2%) which could be due to high prevalence of tuberculosis in the region where the study was done. In the study done by Ripunjaya M[12] reactive lymphadenopathy was observed to be the most frequent diagnosis (34.36%). It was also the most frequent diagnosis in other studies and its incidence was found to range from 18.9% to 42%.[13-16] The high incidence may be due to the high prevalence of tuberculosis in India. For unknown reasons, the right supraclavicular lymph nodes were more frequently involved than the left supraclavicular lymph nodes which could be an incidental finding.

Lymphoid malignancy represents a minority of the tumours (7-13%)[8] in other studies as well as in our study (4.4%). As was the case in previous report,[8] lymphoid malignancy represented a minority of the tumors in the current study. In study done by Ripunjaya M[12] he diagnosed (22.25%) neoplastic lesions in the lymph nodes by FNAC, of which more cases of metastatic involvement (82%) rather than lymphoma (18%) were seen. This was similar to other studies of India origin.[14,17] Other studies have found the incidence of neoplastic involvement to vary from 10.1% to 47.8%.[15,18-20] A Brazilian FNAC study on lymph nodes diagnosed 79.4% metastasis and 14.2% lymphomas.[21] But a study conducted in Egypt has reported more involvement by lymphomas (80.3 %) rather than metastatic diseases (19.7 %).[22]

Small cell carcinoma of the lung can metastasize to the supraclavicular lymph nodes and this results in an unfavorable prognosis.[23] We found all small cell carcinomas in supraclavicular lymph nodes to arise from the lungs. Our data concurs with the observation that most adenocarcinomas metastasize to the left supraclavicular lymph node. In this study, squamous cell carcinomas show no predilection to the side that they metastasize to. In contrast, Carson HJ et al[7], found that squamous cell carcinomas appeared to favor the right side. The cause for this remains unclear and it could be just an incidental finding. Small cell carcinomas did not show a sidewise predilection in this study which was also reported by Adhikari RC[5] in his study. This study shows that metastatic tumors are more common in supraclavicular lymph nodes than the lymphoid malignancy.[7,8,10]

Based on the finding in our study we found that FNAC is an extremely useful tool in the evaluation of palpable cervical lymph node, in majority of the cases excluding the need of a more invasive procedure and helping to initiate the appropriate treatment. The ancillary techniques such as immunohistochemistry may be employed whenever sufficient material is available for cell blocks and this would help in establishing the diagnosis.

CONCLUSION:

FNAC is an important diagnostic tool for diagnosing benign as well as malignant lesions. It is a safe, simple and inexpensive definite diagnostic procedure to render a prompt diagnosis, especially in lymph node aspirates, where biopsies are not done commonly. It can also pick up unsuspected malignancies. In the present study, the predominant cause of enlarged neck nodes was tubercular lymphadenitis, followed by reactive lymphadenitis, granulomatous lymphadenitis and malignant neoplasm especially metastatic carcinoma and lymphomas. The limitations faced are with necrotic lymphadenopathy, where if the clinician is unsatisfied with the cytological diagnosis, a lymph node biopsy is helpful to make a correct diagnosis.

REFERENCES

1. Fatima S, Arshad S, Ahmed Z, Hasan S. Spectrum of cytological findings in patients with neck lymphadenopathy-Experience in a tertiary care hospital in

Pakistan. Asian Pac J Can Prev 2011;12: 1873-75.
2. Russel RCG, William NS, Bulstrode CJK (2004). Bailey and Love's short practice of surgery. 24th ed. London: Arnold.
3. Ahmed T, Naeem M, Ahmad S, Samad A, Nasir A. Fine needle aspiration cytology and neck swellings in the surgical outpatient. J Ayub Med Coll. 2008;20 : 30-32.
4. Sriwatanawangsa V, Cardoso R, Chang P. Incidence of malignancy in peripheral lymph node biopsy. Am Surg 1985;51:587-90.
5. Adhikari RC, Jha A, Sayami G, Shrestha S, Sharma SK. Fine needle aspiration cytology of palpable supraclavicular lymph nodes. J of Pathol of Nepal 2011;1:8-12.
6. Gupta RK, Naran S, Lallu S, Fauck R. The diagnostic value of fine needle aspiration cytology (FNAC) in the assessment of palpable supraclavicular lymph nodes: a study of 218 cases. Cytopathology 2003;14:201-7.
7. Carson HJ, Candel AG, Gattuso P, Castelli MJ. Fine-needle aspiration of supraclavicular lymph nodes. Diagn cytopathol 1996;14:216-20.
8. Nasuti JF, Mehrotra R, Gupta PK. Diagnostic value of fine-needle aspiration in supraclavicular lymphadenopathy: a study of 106 patients and review of literature. Diagn Cytopathol 2001;25:351-5.
9. Cervin JR, Silverman JF, Loggie BW, Geisinger K. Vichow's node revisited: analysis with clinicopathologic correlation of 152 fine needle aspiration biopsies of supraclavicular nodes. Arch Pathol Lab Med 1995;119:727-30.
10. McHenry CR, Cooney MW, Slusarczyk SJ, Khiyami A.Supraclavicular lymphadenopathy: the spectrum of pathology and evaluation of fine-needle aspiration biopsy. Am Surg 1999;65:742-6.
11. Gupta N, Rajwanshi A, Srinivasan R, Nijhawan R. Pathology of supraclavicular lymphadenopathy in Chandigarth, north India: an audit of 200 cases diagnosed by needle aspiration. Cytopathology 2006;17:94-6.
12. Ripunjaya M. Anne W. Utility of fine needle aspiration cytology of lymph nodes. IOSR Journal of Dental and Medical Science 2013;8:13-18.
13. Kochhar K, Patel B, Shah M. Pattern of Lymphadenopathy on Fine Needle Aspiration Cytology of Superficial Lymph Nodes (A Study of 150 Cases) Journal Of Advance Researches In Biological Sciences.2012 ; 4: 288-92.
14. Khajuria R, Goswami KC, Singh K, Dubey VK. Pattern of Lymphadenopathy on Fine Needle Aspiration cytology in Jammu. JK Science Journal of Medical Education and Research 2006; 8:157-59.
15. Hirachand S, Lakhey M, Akhter J, Thapa B. Evaluation of Fine Needle Aspiration Cytology of Lymph Nodes in Kathmandu Medical College Teaching Hospital. Kathmandu University Medical Journal 2009; 7:139-42.
16. Adhikari P, Sinha BK, Baskota DK. Comparison of fine needle aspiration cytology and histopathology in diagnosing cervical lymphadenopathi- es. Australasian Medical Journal 2011; 4: 97-99.
17. Alam K, Khan AH, Siddiqui FA, Jain A, Haider N. Fine Needle Aspiration Cytology (FNAC), a handy tool for metastatic lymphadenopathy. The Internet Journal of Pathology 2010;10:1528-8307.
18. Paul PC, Goswami BK, Chakrabarti S, Giri A, Pramanik R. Fine Needle Aspiration Cytology of Lymph Nodes - An institutional study of 1448 cases over a five year period. Journal of Cytology 2004; 21:187-90
19. Ahmad T, Naeem M, Ahmad S, Samad A, Nasir A. Fine Needle Aspiration Cytology (FNAC) and Neck swellings in the surgical department. Journal of Ayub Medical College Abbottabad 2008; 20:30-32.
20. Ghartimagar D, Ghosh A, Ranabhat S, Shrestha MK, Narasimhan R, Talwar OP. Utility of fine needle aspiration cytology in metastatic lymph nodes. Journal of Pathology of Nepal 2011; 1: 92-95.
21. Martin MR, Santos GC. Fine Needle Aspiration Cytology in the diagnosis of superficial lymphadenopathy: a 5 year Brazilian experience. Diagn Cytopathol 2006; 34:130-134.
22. Hafez NH, Tahoun NS. Reliability of fine needle aspiration cytology (FNAC) as a diagnostic tool in cases of cervical lymphadenopathy. Journal of the Egyptian

National Cancer Institute 2011; 23: 105–114

23. Spiegelman D, Maurer LH, Ware JH et al. Prognostic factors in small cell carcinoma of the lung: an analysis of 1521 patients. J Clin Oncol 1989;7:344-54.