REVIEW ARTICLE

Rapid Diagnosis of Fungal Infection by Calcofluor-White Stain

Arti Singh Rajput[1], Satpal Yadav[2], Praveen Singh Rajput[3], Babita Singh Rajput[4]

ABSTRACT

The diagnosis of fungal infection is a variable subject in current time. This review article provides information of different stains and utility of Calcofluor-White stain (CFW) in rapid diagnosis of fungi in cytopatholgy and histopathology without interfere with subsequent stains such as Gram's, PAS, GMS.

Keywords: Fungal infection, CFW, GMS, PAS

How to cite this article: Arti Singh Rajput, Satpal Yadav, Praveen Singh Rajput, Babita Singh Rajput. Rapid diagnosis of fungal infection by Calcofluor-White stain. International Journal of Contemporary Medical Research. 2015; 2(2):196-199

[1]Dental S.R., Baba Saheb Ambedkar hospital, Delhi, [2]Senior Pediatric consultant, Jaipur Golden hospital and Gupta hospital, Delhi, [3,4]Medical officer, GRMC, Gwalior, M.P, India

Corresponding author: Dr. Arti Singh Rajput, Dental S.R., Baba Saheb Ambedkar hospital, Delhi, India

Source of Support: Nil

Conflict of Interest: None

INTRODUCTION

Fungal infections are most commonly seen in human beings such as candidiasis, most commonly caused by Candida, species candida albicans. Various fungi may harbour in healthy adults (approximately 60%) and healthy children (45 to 65%) without demonstrating any clinical signs or symptoms.Under a variety of pathologic conditions, Candida can proliferate in the mouth and produce oral lesions. Many predisposing factors have been identified as playing a significant role in the development of oral candidiasis. Low salivary secretion, poor oral hygiene, removable intraoral prosthesis, inhaled corticosteroid therapy, chronic antibiotic therapy, diabetes, systemic steroid therapy, immunologic impairment (HIV infection), lymphoma, leukemia and anaemia have all been associated with increased susceptibility for oral candidiasis.[1]

Oral candidiasis is considered as a sentinel opportunistic infection in HIV disease. Between 11% and 96% of patients with HIV infection develop oral canididiasis at some stage of their disease process while on an average one in the three individuals are affected at any one time. Furthermore, it is considered to be a marker disease with prognostic implications as to the development of AIDS. The most recent classification or oral manifestation in HIV infection distinguishes between the pesudomembranous and erythmatous variants of oral candidal infection.[2] Thus, it would seem that oral candidosis are likely to be relatively widely prevalent in the future years because of the global spread of HIV infection.[3]

Not only with AIDS but also with the various precancerous lesions and cancers, the association of Candida to the extent of its causative agent has been reported in the literature.[3]

Oral leukoplakia occurs in 3% to 4% of the adult population and if untreated, 5% to 10% of the cases will develop into carcinoma. The association of leukoplakia with yeasts, in particular Candida albicans, has already been noted by Jepsen and Winther,[4] Rindum JL, Stenderup, A Holmstrup P.,[5]Lynch Denis et al.[6] By means of mycologic isolation technique, they found yeasts in a high proportion of leukoplakias, particularly in lesions of the speckled type, an entity now termed nodular type. Since then, a number of studies have confirmed that a considerable proportion of leukoplakias are associated with yeasts. The exact extent of such an association, however is influenced by the technique used for isolation and identification of the yeasts and by the type of leukoplakia from which the yeasts have been isolated. Whether the yeasts are causally involved in the development of leukoplakia, or just secon-

dary invaders in already established lesions, is a matter still being debated (Krogh et al, 1987a; Sciubba, 1995).[7] It has been suggested that candidal infection may be a factor in the malignant transformation of leukoplakia.[8]

C. albicans infection, together with simultaneous existence of several etiological factors, seems to play a role in the malignant transformation (Anoczy, 1977 and Krogh et al., 1987b).[7] There is considerable circumstantial evidence to suggest that Candida species play a role in oral carcinogenesis.[9] It has been hypothesized that certain Candida types from oral leukoplakia have higher nitrosation potentials than others, which might indicate a possible role of specific yeast types in the transformation of leukoplakia into carcinoma (Krogh et at., 1987). In light of their hypothesis, an additional plausible etiological explanation could be alcohol drinking and consequent high acetaldehyde production via reversed ADH-mediated reaction by certain C. albicans strains.[7]

Yeasts have also been identified in oral lichen palnus lesions, and development of malignant conditions in oral lichen planus lesions has been reported. There are no data indicating that yeast infection is involved in the etiology oral lichen planus. Yeasts may, however, be involved in the malignant transformation in some cases of oral lichen planus.[10]

Candida carriage in the general population is dependent on several factors, including age, salivary factors, immune status, and other systemic factors. Some authors have shown that Candida organisms are most prevalent on the tongue, followed by buccal mucosa, and the palate.

It has been recently suggested that the mucosal alterations in OSMF, especially of the epithelium, act as a platform for increased candidal colonization, thus affecting the biological behavior of the disease process.[11,12]

Diagnosis of fungal infection is most often made by visually. It may be confirmed by microbiology. Subclinical carrier state of this disease is diagnosed with use of oral rinses, swabs, smears and imprint/impression cultures.[12]

Arriving at the diagnosis of Candida is a complex subject. As is the case in other infectious diseases, a definitive clinical diagnosis of oral candidosis depends to a greater or lesser extent upon the laboratory identification of pathogenic Candida species by mycological and or histopathologic techniques. Isolation and recognition of a definitive pathogen such as Mycobacterium tuberculosis may impose no further obligations on the examining laboratory and the clinical diagnosis may be confirmed solely by establishing its identity.[3]

However, when the association between an organism and its host ranges from that of an innocuous commensal to a primary pathogen, as in oral candidosis, there is an additional onus on the laboratory to establish the clinical significans of isolate. Therefore, both the laboratory results and clinical data are essential to establish a clinical diagnosis of oral candidosis, as in many situations, the dividing line between health and disease is rather hazy.[3]

STAINING FOR CYTOPATHOLOGY:

Bradley G, Anthony M, Setoand Lamey et al. have used Gram stain as a basic stain for microbial identification of Candida.[3]

Diagnosis of fungal infections may be established by either culture or microscopic observations of yeasts or fungal hyphae. However, since it is often difficult to observe fungi in exfoliative cytology material stained by hematoxylin & eosin (H &E) and Papanicolaou (PAP) staining, one must often resort to other staining methods, such as Gomori Methenamine silver (GMS) or Periodic acid Schiff's (PAS) stain. But these methods are rather slow and take time for fungal demonstration.[3,13] Monheit introduced in their study, addition of utility of CFW stain, without altering the diagnostic cytopathological features, while still allowing the fungi to be identified.[13]

STAINING FOR HISTOPATHOLOGY:

Hematoxylin & eosin (H&E) is a versatile stain to detect micro organisms. It is the stain of choice to confirm the presence of naturally pigmented fungal elements, and to demonstrate the nuclei of yeast-like cells.

There are number of drawback of H&E in diagnosis of fungi. It is often difficult to distinguish poorly stained fungal fragments from tissue sections. Some times the morphological features may not be evident or misleading e.g. cytoplas-

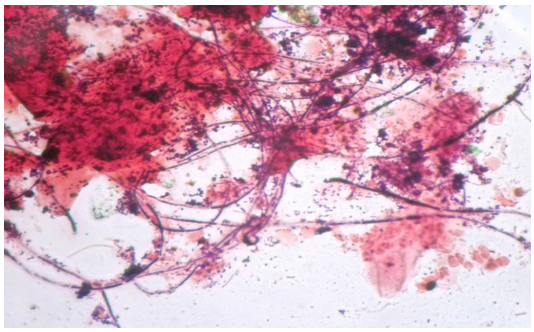

Figure-1: Candidal hyphae stained by Gram's stain in cytopathological smear (Light microscope, 40X with zoom)

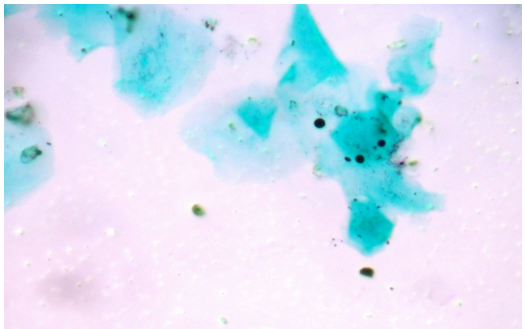

Figure-2: Candidal spores stained by GMS stain in cytopathological smear (Light microscope, 40X with zoom)

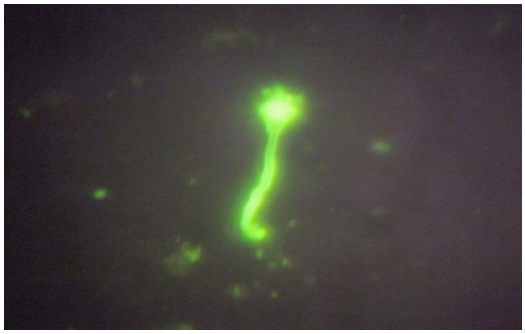

Figure-3: Candidal hyphae stained by CFW stain in cytopathological smear (Fluorescence microscope, 40X with zoom)



Figure-4: Candidal hyphae stained by CFW stain in histopathological section (Fluorescence microscope, 40X with zoom)

mic retraction artefact in the sections.[14]

Many studies,such as Bradly G. S.utilized the PAS stain to confirm the diagnosis of C. albicans in ulcerated oral tissues, Jeffery Johnson demonstrated candidal presence using PAS stain in a patient of chronic atrophic oral candidiasis.[3]

Various studies, such as those by Seto, Fotos et al. and Barrett et al. recommended the use of PAS stain for the detection of fungi and Zebrin, Cawson and Lehner demonstrated the presence of Candida in oral candidal leukoplakia by using PAS stain.[3] Gomori Menthenamine silver (GMS) and Periodic acid Schiff (PAS) stain are special stains which perform equally in the screening of fungi. But PAS stain demonstrates better morphology of fungi than GMS. GMS is preferred for screening, because it gives better contrast, and stains even degenerated and nonviable fungi that are sometimes refractory to the other stains.[12]

Jacqueline E., Monheit et al., Anna R. Graham et al. in their study used GMS and CFW stain to demonstrate fungal infections in tissue sections.[3]

Denis P. Lynch et al. worked on histopathological sections of oral candidiasis with CFW and GMS stain. They observed similar positivity in both staining.[6]

The disadvantage of GMS fungal stain is that they mask the natural colour of pigmented fungi, making it impossible to determine whether a fungus is colourless hyaline or dematiaceous (pigmented). Except for the PAS reaction, fungal stain GMS do not adequately demonstrate the inflammatory response to fungal invasion. To counteract this, a GMS-stained section can be counterstained with H&E for a simultaneous study of the fungus and the host response.[12]

CONCLUSION

We concluded that Fungi can be recognized by the use of standard staining methods, such as H & E, PAS and Gomori Methenamine silver (GMS), but these organisms may be obscured on H & E and the latter two methods are slower than Calcofluor white staining (CFW). It does not interfere with the subsequent Gram or PAS staining when required. Calcofluor White staining has a number of advantages over traditional methods. The technique is extremely rapid, requiring less than 30 seconds from preparation

of hydrated specimen to viewing of the slide. No specific techniques are required other than routine histological processing and it does not disturb the cellular details.

REFERENCES

1. Navazesh Mahvash, Wood Gary J., Brightman Vernon J. Relationship between salivary flow rates and Candida albicans counts. Oral Surgery, Oral Medicine Oral Pathology 1995; 80: 284-8.
2. Fotos Pete. G., Vincent Steven D., Hellstein John W. Oral candidosis, Oral surg Oral Med Pathol 1992; 74: 41-9.
3. Kumar RS, Ganvir SM, Hazarey VK. Candida and Calcofluor White: Study in precancer and cancer. JOMFP 2009; 13 (1): 2-8.
4. JK Savita, HC Girish, Murgod Sanjay, Kumar Harish. Oral submucous fibrosis: A review [part 2].Journal of Health Sciences and Research 2011;2: 1-6.
5. Lehner Thomas. Chronic candidiasis. British Dental Journal 1964; 16:539-45.
6. Lynch Denis, Gibson Deborah K. The use of Calcofluor White in the histopathologic diagnosis of oral candidiasis Oral Surg. Oral med. Oral pathol 1987;63: 698-703.
7. Tillonen J., Homann N., Rautio M. Et al. Role of yeasts in the salivary acetaldehyde production from ethanol among risk group for ethanol Associated oral cavity cancer. Alcohol Clin Exp Res 1999; 23 (8):1409-15.
8. Krogh P., Holmstrup P., Thorn JJ, Vedtofte P, Pindborgjj. Yeast species and biotypes associated with oral leukoplakia and lichen planus. Oral Surg Oral med Oral Pathol 1987;63:48-54.
9. Field E. A., Field J. K., Martin M. V. Does Candida have a role in oral epithelial neoplasia? Journal of medical and veterinary mycology 1989;27: 277-94.
10. Samaranayake LP, Holmstrup P. Oral candidiasis and human immunodeficiency virus infection. J Oral Pathol Med 1989; 18: 554-64.
11. Kamat, M. S., Vanaki, S. S., Puranik, R. S., Puranik, S. R. and Kaur, R. Oral Candida carriage, quantification, and species characterization in oral submucous fibrosis patients and healthy individuals. Journal of Investigative and Clinical Dentistry 2011; 2:3-12
12. Haque Abida. Special stains use in fungal infections. Connection 2010;1:187-94.
13. Rapid Detection of fungi in tissues using Calcofluor White and fluorescence microscopy. Jacqueline E. Monheit, MD; Daniel F. Cowan, MD; David G. Moore, PhD. Rapid Detection of fungi in tissues using Calcofluor White and fluorescence microscopy. Arch pathol Lab Med 1984; 108: 616-8.
14. Woods Gail L., Walker David H. Detection of infection or infectious agents by use of cytologic and histologic stains. Clinical microbiology reviews. 1996;9:382–404.